

Ocena skuteczności leczenia ortopedyczną maską twarzową przy użyciu sztucznej inteligencji na dwuwymiarowych fotografiach

Evaluation of the Effectiveness of Orthopedic Face Mask Treatment Using Artificial Intelligence on Two-Dimensional Photographs

Sertan Soyulu¹ **A B D F** (ORCID ID: 0000-0003-3380-7508)
Gokhan Coban¹ **A C F** (ORCID ID: 0000-0001-6066-005X)
Taner Ozturk¹ **A C E F** (ORCID ID: 0000-0003-1670-286X)
Saniye Merve Cengiz² **D F** (ORCID ID: 0000-0003-0803-8735)

Wkład autorów: **A** Plan badań **B** Zbieranie danych **C** Analiza statystyczna **D** Interpretacja danych
E Redagowanie pracy **F** Wyszukiwanie piśmiennictwa

Authors' Contribution: **A** Study design **B** Data Collection **C** Statistical Analysis **D** Data Interpretation
E Manuscript Preparation **F** Literature Search

¹ Zakład Ortodoncji, Wydział Stomatologii, Uniwersytet Erciyes, Turcja
Department of Orthodontics, Faculty of Dentistry, Erciyes University, Turkey

² Zakład Ortodoncji, Wydział Stomatologii, Uniwersytet Mersin, Turcja
Department of Orthodontics, Faculty of Dentistry, Mersin University, Turkey

Streszczenie

Zabieg protrakcji szczęki z użyciem ortopedycznej maski twarzowej jest metodą często stosowaną u pacjentów ze szkieletowymi wadami zgryzu klasy III z powodu retrognacji szczęki. **Cel.** Celem tego badania jest ocena zmian parametrów mierzonych na dwuwymiarowych zdjęciach czołowych i profilowych wykonanych na początku (T0) i na końcu (T1) leczenia z zastosowaniem ortopedycznej maski twarzowej u pacjentów ze szkieletowymi wadami zgryzu

Abstract

Maxillary protraction procedure with an orthopedic face mask is a method frequently used in patients with skeletal Class III malocclusion due to maxillary retrognathia. **Aim.** The aim of this study is to evaluate the changes in the parameters measured in two-dimensional frontal and profile photographs taken at the beginning (T0) and at the end (T1) of orthopedic face mask (FM) treatment in patients with skeletal Class III malocclusion, using artificial intelligence (AI). **Material and**

Adres do korespondencji/*Correspondence address:*

Taner Ozturk
Orthodontics, Erciyes University,
Faculty of Dentistry, 38039, Kayseri, Turkey
e-mail: tanertr35@gmail.com



Copyright: © 2005 Polish Orthodontic Society. This is an Open Access journal, all articles are distributed under the terms of the Creative Commons Attribution-NonCommercial-ShareAlike 4.0 International (CC BY-NC-SA 4.0) License (<http://creativecommons.org/licenses/by-nc-sa/4.0/>), allowing third parties to copy and redistribute the material in any medium or format and to remix, transform, and build upon the material, provided the original work is properly cited and states its license.

klasy III, przy użyciu sztucznej inteligencji (AI). **Materiał i metody.** Do badania włączono łącznie 23 pacjentów ze szkieletowymi wadami zgryzu klasy III leczonych ortopedyczną maską twarzową. W tym badaniu oceniono osiem parametrów: kąt nosowo-wargowy, kąt bródkowo-wargowy, kąt projekcji podbródka, kąt A'B' w płaszczyźnie frankfurckiej, stosunek górnej wargi do dolnej wargi, stosunek środkowej części twarzy do dolnej części twarzy, górna warga - linia E, dolna warga - linia E. **Wyniki.** Z wyjątkiem kąta nosowo-wargowego zaobserwowano znaczące zmiany we wszystkich parametrach między pomiarami w punkcie czasowym T0 i T1. Stwierdzono umiarkowanie ujemną korelację między kątem utworzonym przez kąt A'B' w płaszczyźnie frankfurckiej a stosunkiem górnej wargi do dolnej wargi i odległością między górną wargą a linią E. Stwierdzono umiarkowanie dodatnią korelację między odległością dolnej wargi od linii E a stosunkiem środkowej i dolnej części twarzy oraz odległością górnej wargi od linii E. **Wniosek.** Zastosowanie analizy z wykorzystaniem AI jest skuteczną, łatwą i niedrogą metodą oceny zmian w strukturach twarzy spowodowanych leczeniem u pacjentów z wadami zgryzu klasy III. (Soylu S, Coban G, Ozturk T, Cengiz SM. Ocena skuteczności leczenia ortopedyczną maską twarzową przy użyciu sztucznej inteligencji na dwuwymiarowych fotografiach. *Forum Ortod* 2023; 19 (3): 77-83).

Nadesłano: 22.08.2023

Przyjęto do druku: 16.10.2023

<https://doi.org/10.5114/for.2023.134497>

Słowa kluczowe: sztuczna inteligencja, wada zgryzu klasy III, zdjęcie zewnątrzustne, maska twarzowa

Introduction

Skeletal Class III malocclusion is an orthodontic and orthopedic problem resulting from an incompatibility of the sagittal dimension of the maxilla and mandible. It is less common than other craniofacial anomalies and is very difficult to treat (1,2). Although its incidence varies between societies, the incidence of Class III malocclusion was found to be 10%–12% in studies conducted in the Turkish population (3). Class III malocclusions may be caused by maxillary retrognathia, mandibular prognathia, or a combination of both (4). Class III malocclusions have a multifactorial etiology that includes genetic and environmental factors (5).

Treatments of skeletal Class III malocclusions vary depending on the severity of the anomaly, the jaw affected, and the growth and development stage of the patient (6,7). Functional orthopedic treatment options can be applied in patients with Class III malocclusion during the growth and development period, while camouflage treatment or orthognathic surgical treatment can be applied depending on the

methods. A total of 23 patients with skeletal Class III malocclusion receiving orthopedic FM treatment were included in the study. Eight parameters were evaluated in this study: Nasolabial Angle, Mentolabial Angle, Chin Projection Angle, Frankfurt Horizontal–A'B' angle, Upper Lip/Lower Lip Ratio, Midface/Lower Face Ratio, Upper Lip–E-Line, Lower lip – E-line. **Results.** Except for the Nasolabial Angle, significant changes were observed in all parameters between the T0 and T1 measurements. A moderate negative correlation was found between the angle formed by the Frankfurt Horizontal–A'B' angle and the Upper Lip/Lower Lip Ratio and Upper Lip–E-line distance. A moderate positive correlation was found between the distance of the Lower Lip to the E-line and the Midface/Lower Face Ratio and Upper Lip to E-line distance. **Conclusion.** The use of analysis with AI is an effective, easy, and inexpensive method to evaluate changes in facial structures caused by treatment in patients with skeletal Class III malocclusion. (Soylu S, Coban G, Ozturk T, Cengiz SM. Evaluation of the Effectiveness of Orthopedic Face Mask Treatment Using Artificial Intelligence on Two-Dimensional Photographs. *Orthod Forum* 2023; 19 (3): 77-83).

Received: 22.08.2023

Accepted: 16.10.2023

<https://doi.org/10.5114/for.2023.134497>

Key words: Artificial intelligence, Class III malocclusion, Extraoral photograph, Face Mask

severity of the anomaly in patients who have completed growth and development (6,8).

Orthopedic face mask (FM) treatment, which is used to correct skeletal Class III malocclusion in individuals during growth and development, is one of the most preferred methods for the treatment of individuals with skeletal Class III malocclusion due to maxillary retrognathia because it provides forward movement of the maxilla and limits the growth of the mandible (9). In addition to providing an orthopedic effect that moves the maxilla forward in the sagittal direction, orthopedic treatment using an FM applied before the growth spurt generally causes a counterclockwise rotation of the maxilla and a clockwise rotation in the mandible (10,11).

In the Kılıçoğlu and Kırılıç study reported that a decrease in the concavity of the profile with orthopedic FM treatment. This was attributed to a slight inhibition of the forward movement of the lower lip, repositioning of the soft tissue pogonion backward, and forward displacement of the upper lip (12).

Evaluation of the Effectiveness of Orthopedic Face Mask Treatment ...

Many researchers have detected significant changes in the soft tissue profile because of the forward movement of the upper lip with FM treatment (11,13,14). Some researchers have reported a significant retroclination of the lower incisors along with a backward movement of the lower lip because of in treated with maxillary protraction treatment using an FM (11,15), while others have reported no significant change in the position of the lower lip (12). When planning an orthodontic treatment, cephalometric and posteroanterior radiographs, dental models, and intraoral and extraoral photographs are primarily used. Clinical intraoral and extraoral photographs are useful and necessary for orthodontists (16,17). However, most of the artificial intelligence (AI) studies related to orthodontics have focused on 2-dimensional (2D) or 3D digital radiographs (18-20). To present knowledge, only a few studies have focused on digital orthodontic photographs (21, 22).

Aim

The aim of this retrospective study is to evaluate the changes in the parameters measured on 2D frontal and profile photographs taken at the beginning and end of orthodontic FM treatment using AI. The null hypothesis of the study is that there will be no significant change in soft tissue measurements in two-dimensional photographs after face mask treatment in individuals with skeletal class III malocclusion.

Material and methods

The ethical approval required at the beginning of the study was obtained from the Clinical Research Ethics Committee of Erciyes University (Approval no: 2023/264; Approval Date: 04/12/2023). An informed consent form was obtained from all patients and their parents. According to the power analysis performed with the G*Power software (ver. 3.1.9.7, Heinrich Heine University, Duesseldorf, Germany) using the pre- and post-treatment values of the Upper Lip - E line distance in the study of Yavuz et al. before the study using similar treatment mechanics, alpha 0.05, d= 0.636 and 85% power unidirectional paired samples t (23-24). According to the test, it was determined that at least 20 patients should be taken. In order not to jeopardize the study safety, 23 patients were included. In this study, 23 individuals (15 males and 8 females, mean age: 11.64 ± 1.16 years) with skeletal Class III malocclusion who applied to the Department of Orthodontics at Erciyes University Faculty of Dentistry for treatment were examined. The orthopedic FM treatment was applied to these individuals and changes were evaluated using 2D frontal and profile photographs taken before and after treatment.

Patients with an ANB angle between -5° and 0° , an SN-GoGN angle between 26° and 38° with normal vertical growth,

no previous orthodontic treatment, all maxillary incisors, and first permanent molars erupted, and either an edge-to-edge or a crossbite relationship in the anterior and without any craniofacial deformities were included in this study.

Before applying the FM, the screw (Forestadent Co., Pforzheim, Germany) of the McNamara-type rapid maxillary expansion device (Fig. 1A) was turned twice per day for a week. After one week, a Petit-type FM (American Orthodontics, Sheboygan, WI, USA) was applied by hanging elastics on hooks placed between the lateral and canine teeth on the right and left sides of the bonded rapid maxillary expansion appliance, applying approximately 350g of force unilaterally and forming an angle of 20° - 30° with the occlusal plane (Fig. 1B). Measurements were taken on frontal and profile photographs obtained before (T0) and after (T1) the FM treatment, which lasted an average of 0.87 ± 0.15 years for the individuals included in the study. An individual premium account was created on the WebCeph website (<https://webceph.com>; Assemblecircle, Seoul, South Korea) for this study.

Photographs were taken of all individuals participating in the study and the Frankfurt horizontal plane and the line passing through the pupils in the frontal view were drawn parallel to the ground (Tab. 1, Fig. 2AB). Photographs of everyone were uploaded to the system separately and the drawing processes on the photos were completed in a few seconds by the website. The images were automatically processed by the deep learning-based program and the uploader changed the orthodontic analysis points if necessary. All measurements were obtained from the WebCeph database for each image.

Statistical analysis

The Statistical Package of Social Sciences (SPSS) software (Ver. 24.0, IBM, Armonk, NY, USA) was used for statistical analysis of the data. Differences between genders were evaluated using the independent samples t-test. Because no significant differences were observed, the data were evaluated as a single group. Normality analysis was performed using the Shapiro-Wilk test. Due to the normal distribution of all data, paired samples t-tests were used for pre- and post-treatment evaluations. The Pearson correlation coefficient was used to evaluate the relationship between the changes that occurred after the end of treatment. In addition, correlation coefficient results; insignificant: 0.00-0.10; weak: 0.10-0.39; medium: 0.40-0.69; strong: 0.70-0.89; and 0.90-1.00 is rated as very strong (25). A p-value of less than 0.05 was considered statistically significant.

Results

When comparing the T0 and T1 measurements, it was observed that there was a statistically significant change in all parameters except for the nasolabial angle (Tab. 2).

Table 1. Figures 3 and 4 are descriptions of the measurements shown

<i>Nasolabial Angle</i>	<i>The angle measured between the columella of the nose and the upper lip. The angle ranges between 85 and 105 degrees and is affected by the anatomical structure of the nasal columella as well as the position and angle of the upper incisors.</i>
<i>Mentolabial Angle</i>	<i>This angle is formed by the intersection of the lower lip and the soft tissue of the chin. The angle should be 120 ± 10 degrees.</i>
<i>Chin Projection Angle</i>	<i>The angle between the facial line defined by the soft tissue nasion and pogonion points and the Frankfurt Horizontal plane.</i>
<i>The Frankfurt Horizontal – A' B' Angle</i>	<i>Angle between the Frankfurt Horizontal and the soft tissue A point (the deepest point of the contour between the subnasale and the upper lip) and the soft tissue B point (the deepest point of the contour between the lower lip and the chin).</i>
<i>Upper Lip/Lower Lip Ratio</i>	<i>The ratio of the length of the upper lip (distance between the subnasale point and the inferior border of the upper lip) to the length of the lower lip (distance between the soft tissue menton and the superior border of the lower lip).</i>
<i>Midface/Lower Face Ratio</i>	<i>The ratio of midface height (distance between the soft tissue nasion and subnasale points) to lower face height (distance between the subnasale and soft tissue menton points).</i>
<i>Upper Lip – E-line</i>	<i>Ricketts drew a line tangent to the soft tissue chin and nose tip called the aesthetic line (E-line). For the upper lip – E-line measurement, the distance between the most anterior point of the upper lip and the Ricketts' E-line is measured.</i>
<i>Lower Lip – E-line</i>	<i>The distance between the most prominent point of the lower lip and Ricketts' E-line.</i>

Table 2. Comparison table of pre-treatment and post-treatment measurements

<i>Parameters</i>	<i>T0</i>		<i>T1</i>		<i>Changes (T0 to T1)</i>		
	<i>Mean</i>	<i>SD</i>	<i>Mean</i>	<i>SD</i>	<i>Mean</i>	<i>SD</i>	<i>P values*</i>
<i>Nasolabial Angle</i>	110.40	13.12	107.73	9.22	2.67	8.45	0.144
<i>Mentolabial Angle</i>	147.77	12.36	141.79	8.32	5.98	9.39	0.006
<i>The Chin Projection angle</i>	88.03	0.9	88.62	1.20	-0.59	1.17	0.025
<i>The Frankfurt Horizontal - A' B' angle</i>	81.27	3.36	75.06	3.01	6.21	3.30	0.000
<i>Upper Lip / Lower Lip Ratio</i>	0.46	0.07	0.49	0.07	-0.03	0.06	0.017
<i>Midface / Lower Face Ratio</i>	1.03	0.07	0.98	0.09	0.05	0.07	0.001
<i>Upper Lip – E Line (mm)</i>	-5.08	1.90	-2.37	2.22	-2.70	1.78	0.000
<i>Lower lip - E line (mm)</i>	-0.95	2.25	-0.11	2.53	-0.84	1.84	0.039

mm: Millimeter. SD: Standard Deviation. T0: Pre-treatment. T1: Post-treatment. * Results of Paired Samples-t test.

Table 3. Evaluation of the Correlations between Parameters

	<i>Mentolabial Angle</i>	<i>The Chin Projection angle</i>	<i>The Frankfurt Horizontal-A' B' angle</i>	<i>Upper Lip / Lower Lip Ratio</i>	<i>Midface / Lower Face Ratio</i>	<i>Upper Lip – E Line (mm)</i>	<i>Lower lip- E line (mm)</i>
<i>Nasolabial Angle</i>	0.391	-0.073	-0.043	0.245	0.194	-0.200	-0.099
<i>Mentolabial Angle</i>	1	-0.169	0.302	0.074	-0.020	-0.434*	-0.467*
<i>The Chin Projection angle</i>		1	0.292	0.015	-0.060	-0.100	-0.004
<i>The Frankfurt Horizontal- A' B' angle</i>			1	-0.463*	-0.170	-0.603**	-0.047
<i>Upper Lip / Lower Lip Ratio</i>				1	0.433*	0.400	0.337
<i>Midface / Lower Face Ratio</i>					1	0.200	0.454*
<i>Upper Lip – E Line (mm)</i>						1	0.554**

Data was given Pearson correlation coefficients. * Correlation is significant at the 0.05 level. ** Correlation is significant at the 0.01 level.

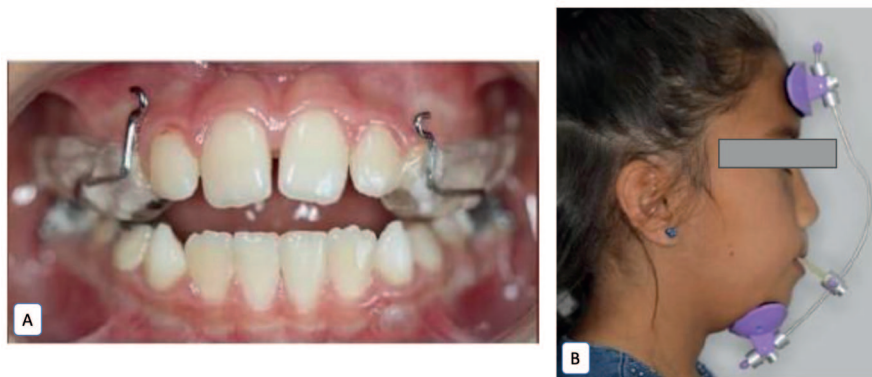


Figure 1. A) McNamara-type rapid maxillary expansion. B) Petit-type face mask.

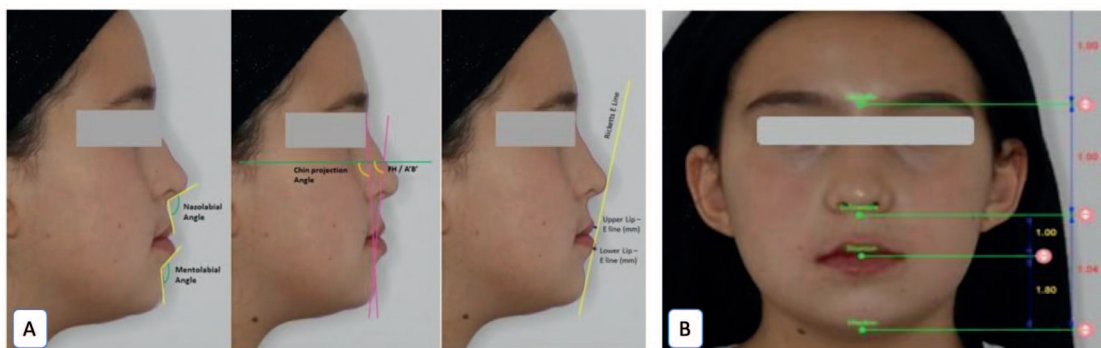


Figure 2. A) Profile photograph parameter measurements. B) Frontal photograph parameter measurements.

With the treatment, mentolabial angle, the Frankfort Horizontal/A'B' line angle, midface/lower face ratio decreased significantly, while chin projection angle, upper and lower lip - E line distances increased significantly (Tab. 2; $p < 0.05$). When evaluating the Mentolabial Angle, a moderate negative correlation was found between the Mentolabial Angle and the Upper Lip - E-line ($r = -0.434$; $p < 0.05$; Tab. 3) and Lower Lip - E-line distances ($r = -0.467$; $p < 0.05$; Tab. 3). A moderate negative correlation was found between the angle formed by the Frankfurt Horizontal line and soft tissue A-B and the Upper Lip/Lower Lip Ratio ($r = -0.463$; $p < 0.05$; Table 3) and Upper Lip - E-line distance ($r = -0.603$; $p < 0.01$; Tab. 3). A moderate positive correlation was found between the distance of the Lower Lip to the E-line and the Midface/Lower Face Ratio and Upper Lip to E-line distance (Tab. 3).

Discussion

The aim of this study is to use AI to evaluate the changes in the measured parameters on 2D frontal and profile photographs taken at the beginning and end of patients' orthopedic FM treatment.

This study included 23 individuals (15 males and 8 females, mean age: 11.64 ± 1.16 years) who were treated with an orthopedic FM for skeletal Class III malocclusion. FM

treatment, which is used for the correction of skeletal Class III malocclusion in individuals in the growth and development period, is one of the most preferred methods to treat individuals with skeletal Class III malocclusion, especially in cases due to maxillary retrognathia, as it provides forward movement of the maxilla and limits the growth of the mandible (9).

Statistically significant differences were detected in all measurements except the Nasolabial Angle (Mentolabial Angle, Chin Projection Angle, The Frankfurt Horizontal - A' B' Angle, Upper Lip/Lower Lip Ratio, Midface/Lower Face Ratio, Upper Lip - E-Line, Lower lip - E-line). If the maxilla is poorly developed vertically and sagittally the mandible continues to grow in the forward direction, resulting in a concave profile; that is, a retruded upper lip and increased nasolabial angle (4,26). Although we observed a decrease in the nasolabial angle with orthopedic FM treatment in this study, it was not statistically significant. Consistent with this result, Kılıçoğlu and Kırılıç did not find a significant difference in the nasolabial angle in patients treated with a De-laire-type FM (12).

It was determined that the mentolabial angle significantly decreased with orthopedic FM treatment. We think that the decrease in the mentolabial angle is due to the upper teeth and lip coming forward to support the lower lip and clockwise rotation in the lower lip. Similarly, to these findings,

Bavbek et al. reported a significant decrease in the mentolabial angle with orthopedic FM treatment (27).

There was a statistically significant decrease in the chin projection angle measurements. This is thought to be due to the backward displacement of the soft tissue pogonion. Ngan et al. reported a similar decrease in the projection angle of the jaw in their study in which they treated class III skeletal malocclusion with a protraction headgear (13). In many studies, it has been shown that the pogonion moves backward and the mandible undergoes posterior rotation (10,11,13).

There was a statistically significant decrease in the Frankfurt horizontal – A' B' angle after treatment. It is thought that this situation is caused by the soft tissue point A moving forward and point B moving backward, as has been shown in many studies before (10,11).

When the upper lip/lower lip ratio was examined, it was observed that there was a greater increase in the length of the upper lip compared to the lower lip during treatment. We think that this is because the upper lip, which was trapped under the lower lip before the treatment, was released and continued to grow vertically because of the treatment's effect. Ngan et al. reported similar results to this study, showing that the growth of the upper lip was more pronounced than that of the lower lip (13).

When the midface/lower face ratio was examined, it was found that there was a statistically significant decrease after FM treatment. This is thought to be due to the mandibular posterior rotation and the increase in the lower facial height. Many studies have shown that the mandible rotates clockwise during FM treatment, causing an increase in the vertical dimension (14, 28).

The distance between the upper lip and E-line decreased significantly with treatment. As the upper dentition and maxilla come forward, the support of the upper lip increases and the upper lip approaches Ricketts' E-line. Like this finding, Kılıçoğlu and Kırılıç reported that the forward movement of the upper lip and backward movement of the soft tissue pogonion bring the upper lip closer to the E-line (12).

The distance between the lower lip and the E-line decreased after FM treatment. It has been predicted to occur due to the relative anterior movement of the lower lip, posterior rotation of the mandible, and backward movement of the soft tissue pogonion. Although some studies have indicated that the lower lip moves backward during treatment (29, 30), others have found a slight inhibition in lower lip growth (12).

For this study, an individual account was created on the WebCeph website (31-33). Photographs were taken of all participants, and the Frankfurt horizontal plane and the line passing through the pupils in a frontal view were both drawn parallel to the ground.

Ryu et al. reported that AI achieved a success rate of 98% in classifying orthodontic photographs taken routinely and suggested that AI should be used in the diagnosis process in orthodontics (22). Further, Çoban et al. used AI while

determining the location of the cephalometric points and stated that despite there being important differences between the cephalometric points determined by AI and those determined by an author of the study, AI is still useful for making a quick preliminary clinical evaluation (19). In addition, Duran et al. reported that the AI-assisted automatic analysis gave similar results with the non-automatic analysis type, according to their study using a similar software (33).

Limitations

The limitations of this study include the small sample size, the loss of depth because of using 2D photographs, and the lack of a control group or radiological assessment. Although AI was used to determine the positions of the points, the positions of the points were changed by the researcher who made the measurements in cases that were thought to be incorrect. Even though the standardization of these analyzes performed on two-dimensional photographs is difficult and this situation creates a limitation, the use of artificial intelligence-based software is increasing, and it is being examined in every field. The results of this study show that analysis using AI can reveal which angles and measures are affected by FM therapy in skeletal Class III patients. Although the use of AI in orthodontic evaluation has become increasingly popular, it is necessary to adjust the points because the auto-drawing is not yet sufficiently developed. The importance of AI is increasing day by day; thus, we think that the benefits of these software will become more important in the future and that the programs will be substantially improved. This study creates a different view for further analysis methods or for examining three-dimensional photographs with AI infrastructure in future studies.

Conclusions

1. The upper lip of the patients moved forward and the pogonion moved backward, resulting in a decrease in the concavity of the profile.
2. By supporting the vertical growth of the midface region, FM treatment increased the midface/lower face ratio.
3. The measurement most correlated with changes in other parameters was the Lower Lip – E-line distance.
4. Using artificial intelligence, evaluations of 2D photos of patients can be made quickly, simply, and relatively reliably.

Conflict of Interest

The authors declare that they have no conflict of interest.

Funding

None.

*Evaluation of the Effectiveness of Orthopedic Face Mask Treatment ...***References**

- Proffit WR, Fields Jr HW, Sarver DM. Contemporary orthodontics. Elsevier 2006.
- Chang HP, Kinoshita Z, Kawamoto T. Craniofacial pattern of Class III deciduous dentition. *Angle Orthod* 1992; 62: 139-44.
- Gelgör İE, Karaman İA, Ercan E. Prevalence of malocclusion among adolescents in central anatolia. *Eur J Dent* 2007; 1: 125-31.
- Guyer EC, Ellis III EE, McNamara Jr JA, Behrents RG. Components of Class III malocclusion in juveniles and adolescents. *Angle Orthod* 1986; 56: 7-30.
- Troy BA, Shanker S, Fields HW, Vig K, Johnston W. Comparison of incisor inclination in patients with Class III malocclusion treated with orthognathic surgery or orthodontic camouflage. *Am J Orthod Dentofacial Orthop* 2009; 135: 146.e1-9.
- Joondeph DR. Early orthodontic treatment. *Am J Orthod Dentofacial Orthop* 1993; 104: 199-200.
- Kluemper GT, Beeman CS, Hicks EP. Early orthodontic treatment: what are the imperatives? *J Am Dent Assoc* 2000; 131: 613-20.
- Campbell PM. The dilemma of Class III treatment: early or late? *Angle Orthod* 1983; 53: 175-91.
- Baccetti T, McGill JS, Franchi L, McNamara Jr JA, Tollaro I. Skeletal effects of early treatment of Class III malocclusion with maxillary expansion and face-mask therapy. *Am J Orthod Dentofacial Orthop* 1998; 113: 333-43.
- Yagci A, Uysal T. Effect of modified and conventional facemask therapy on condylar position in Class III patients. *Orthod Craniofac Res* 2010; 13: 246-54.
- Baccetti T, Franchi L, McNamara Jr JA. Treatment and posttreatment craniofacial changes after rapid maxillary expansion and facemask therapy. *Am J Orthod Dentofacial Orthop* 2000; 118: 404-13.
- Kiliçoğlu H, Kirliç Y. Profile changes in patients with Class III malocclusions after Delaire mask therapy. *Am J Orthod Dentofacial Orthop* 1998; 113: 453-62.
- Ngan P, Hägg U, Yiu C, Merwin D, Wei SH. Soft tissue and dentoskeletal profile changes associated with maxillary expansion and protraction headgear treatment. *Am J Orthod Dentofacial Orthop* 1996; 109: 38-49.
- Kapust AJ, Sinclair PM, Turley PK. Cephalometric effects of face mask/expansion therapy in Class III children: a comparison of three age groups. *Am J Orthod Dentofacial Orthop* 1998; 113: 204-12.
- Vaughn GA, Mason B, Moon H-B, Turley PK. The effects of maxillary protraction therapy with or without rapid palatal expansion: a prospective, randomized clinical trial. *Am J Orthod Dentofacial Orthop* 2005; 128: 299-309.
- Sandler J, Murray A. Digital photography in orthodontics. *J Orthod* 2001; 28: 197-202.
- Sandler J, Dwyer J, Kokich V, McKeown F, Murray A, McLaughlin R, O'Brien C, O'Malley P. Quality of clinical photographs taken by orthodontists, professional photographers, and orthodontic auxiliaries. *Am J Orthod Dentofacial Orthop* 2009; 135: 657-62.
- Spampinato C, Palazzo S, Giordano D, Aldinucci M, Leonardi R. Deep learning for automated skeletal bone age assessment in X-ray images. *Med Image Anal* 2017; 36: 41-51.
- Çoban G, Öztürk T, Hashimli N, Yağci A. Comparison between cephalometric measurements using digital manual and web-based artificial intelligence cephalometric tracing software. *Dental Press J Orthod* 2022; 27: e222112.
- Lee D, Park C, Lim Y, Cho H. A metal artifact reduction method using a fully convolutional network in the sinogram and image domains for dental computed tomography. *J Digit Imaging* 2020; 33: 538-46.
- Li S, Guo Z, Lin J, Ying S. Artificial Intelligence for Classifying and Archiving Orthodontic Images. *Biomed Res Int* 2022; 2022: 1473977.
- Ryu J, Lee Y-S, Mo S-P, Lim K, Jung S-K, Kim T-W. Application of deep learning artificial intelligence technique to the classification of clinical orthodontic photos. *BMC Oral Health* 2022; 22: 454.
- Faul F, Erdfelder E, Lang AG, Buchner A. G*Power 3: A flexible statistical power analysis program for the social, behavioral, and biomedical sciences. *Behavior Res Met* 2007; 39: 175-91.
- Yavuz I, Halicioğlu K, Ceylan I. Face mask therapy effects in two skeletal maturation groups of female subjects with skeletal Class III malocclusions. *Angle Orthod* 2009; 79: 842-8.
- Schober P, Boer C, Schwarte LA. Correlation Coefficients: Appropriate Use and Interpretation. *Anesth Analg* 2018; 126: 1763-8.
- Sanborn RT. Differences between the facial skeletal patterns of Class III malocclusion and normal occlusion. *Angle Orthod* 1955; 25: 208-22.
- Canigur Bavbek N, Balos Tuncer B, Tortop T. Soft tissue alterations following protraction approaches with and without rapid maxillary expansion. *J Clin Pediatr Dent* 2014; 38: 277-83.
- Pavoni C, Masucci C, Cerroni S, Franchi L, Cozza P. Short-term effects produced by rapid maxillary expansion and facemask therapy in Class III patients with different vertical skeletal relationships. *Angle Orthod* 2015; 85: 927-33.
- Franchi L, Pavoni C, Cerroni S, Cozza P. Thin-plate spline analysis of mandibular morphological changes induced by early class III treatment: a long-term evaluation. *Eur J Orthod* 2014; 36: 425-30.
- Masucci C, Franchi L, Defraia E, Mucedero M, Cozza P, Baccetti T. Stability of rapid maxillary expansion and facemask therapy: a long-term controlled study. *Am J Orthod Dentofacial Orthop* 2011; 140: 493-500.
- Mahto RK, Kafle D, Giri A, Luintel S, Karki A. Evaluation of fully automated cephalometric measurements obtained from web-based artificial intelligence driven platform. *BMC Oral Health* 2022; 22: 132.
- El-Dawlatly M, Attia KH, Abdelghaffar AY, Mostafa YA, Abd El-Ghaffour M. Preciseness of artificial intelligence for lateral cephalometric measurements. *J Orofac Orthop* 2023; 9: 1-7.
- Duran GS, Gökmen Ş, Topsakal KG, Görgülü S. Evaluation of the accuracy of fully automatic cephalometric analysis software with artificial intelligence algorithm. *Orthod Craniofac Res* 2023; 26: 481-90.